

## CASE REPORTS

**NEW FOREST  
VETERINARY DENTAL  
SERVICE**  
REFERRAL VETERINARY DENTISTRY AND ORAL SURGERY

We have clinics in Dorset, Devon and Hampshire offering the full range of veterinary dental and oral surgery service

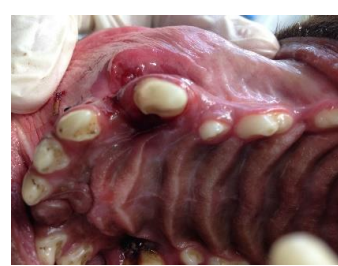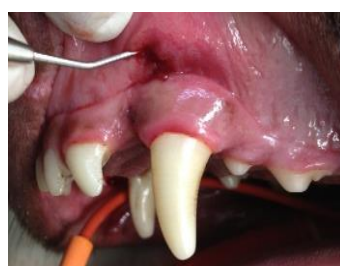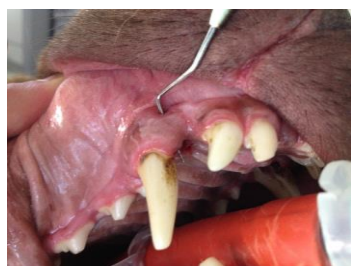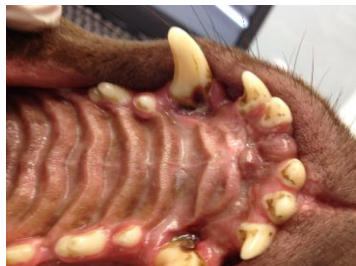Phone or Fax: 02380 891900

[nfvtdentist@btinternet.com](mailto:nfvtdentist@btinternet.com)

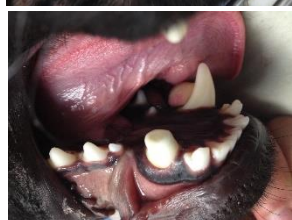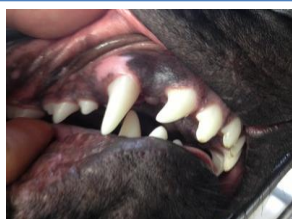
[www.newforest-vetdentist.co.uk](http://www.newforest-vetdentist.co.uk)

### MALOCCLUSIONS

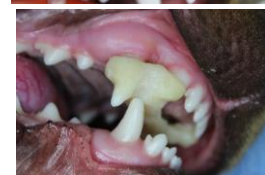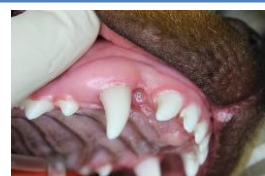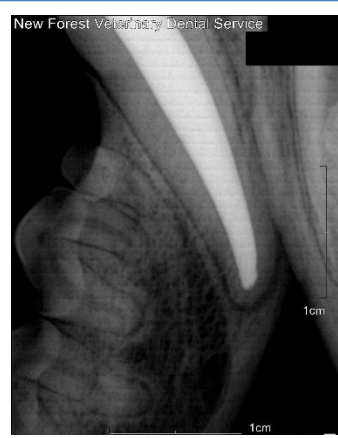*Malocclusions are a common reason for referral to our clinic. They are either caused by an abnormally positioned or angled tooth, abnormal jaw length or size, or a combination of the two. They are significant in that they are a potential cause of persistent chronic oral pain and can cause severe oral lesions.*



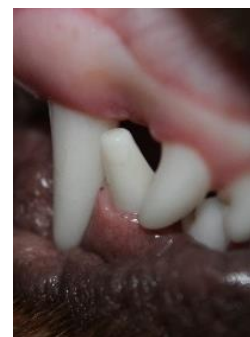These are photographs from a 6 year old Labrador who had a short lower jaw. His lower canine teeth had caused substantial defects in his hard palate, which had then gone on to form two large painful fistulae through his upper jaw. The lesion on the left side had even caused a swelling over his nose, and he gets food and other debris stuck in these defects. He was treated with bilateral crown height reduction.



This 1 year old Labrador also has a short lower jaw with his right lower canine impinging on his hard palate. His lower jaw had become twisted by the malocclusion ('Wry bite'), and he had a large defect in his hard palate from the lower canine tooth. To treat his malocclusion, the crown of his lower canine tooth was shortened, and treated with a root canal treatment as the pulp had been exposed. Within 4 weeks, the defect in his hard palate had completely healed and his jaw was almost completely untwisted.



This young gun dog has a dental malocclusion, whereby the two lower canine teeth are too narrow and are therefore impinging on the hard palate. The defect and resultant inflammation is clearly evident on the photo. An orthodontic device called an 'Incline Plane' was custom made and fitted to the upper teeth. This allowed us to move the lower canine teeth into their normal position, preventing the teeth from damaging the upper jaw.



We are an independent, dental and oral surgery referral practice with clinics in Dorset, Devon and Hampshire. We offer treatment for a range of conditions including root canal treatment for fractured and devitalised teeth, orthodontic treatment of traumatic malocclusions, feline oral diseases including Tooth Resorption and Gingivostomatitis and treatment of oral trauma and neoplasia.

Phone or Fax: 02380 891900 or 07825 416534

Email: [nfvtdentist@btinternet.com](mailto:nfvtdentist@btinternet.com) Website: [www.newforest-vetdentist.co.uk](http://www.newforest-vetdentist.co.uk)